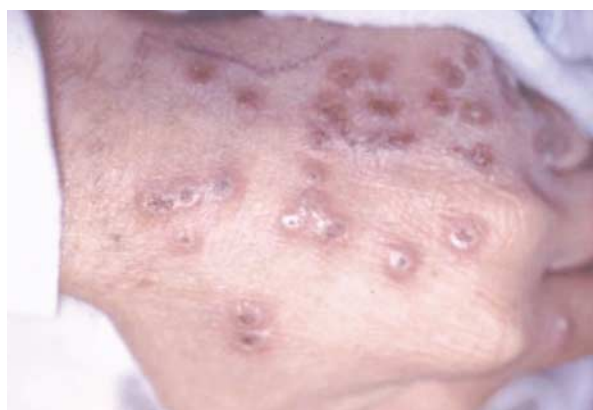
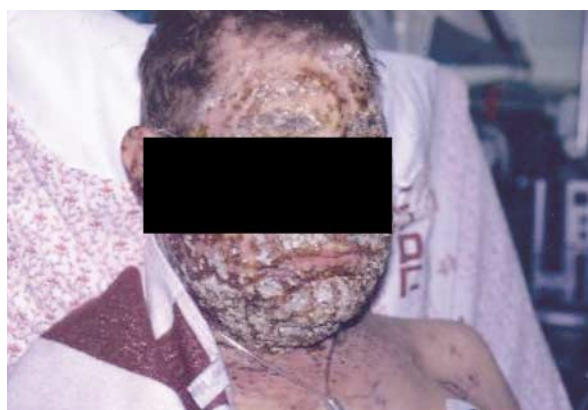



Images in Clinical Medicine



A



B

Eczema Vaccinatum — A Timely Reminder

Ten days after being vaccinated against smallpox, a 27-year-old man was hospitalized with a high fever, facial edema, and an umbilicated, vesicular, crusting rash on his face, neck, upper chest, and hands (Panel A). He had a history of atopic dermatitis. Eczema vaccinatum was diagnosed. As the vesicular rash became disseminated, supraglottic edema with shortness of breath developed. The patient was transferred to the intensive care unit and received vaccinia immune globulin and supportive care. Over the next two weeks extensive crusting of the facial lesions occurred (Panel B). Cultures of vesicular fluid grew vaccinia virus, and skin biopsy showed necrotic epidermal cells with intranuclear inclusions compatible with the diagnosis of eczema vaccinatum. Three weeks after admission, the patient was discharged, with deep facial and chest scars.

Eczema vaccinatum is a rare complication of smallpox vaccination. It develops in patients with a history of eczema who are given the vaccine or who are in close contact with vaccinated persons.

ALLON E. MOSES, M.D.
RONIT COHEN-PORADOSU, M.D.
*Hadassah University Medical Center
Jerusalem 91120, Israel*

Copyright © 2002 Massachusetts Medical Society.

This article was published at www.nejm.org on March 28, 2002.